

SPECIALISTFOCUS

Transradial PCI

Dr Lim Ing Haan, Consultant
Department of Cardiology, Tan Tock Seng Hospital

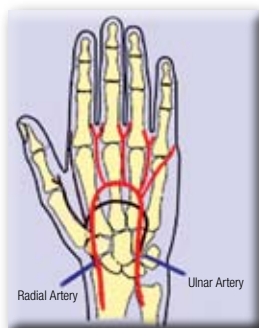

Percutaneous intervention and coronary artery bypass grafting are the two coronary revascularisation techniques to treat ischemic heart disease. In PCI, the technique involves gaining arterial access via the femoral or radial arteries. Under fluoroscopy, a guidewire is passed into the coronary artery and across the stenosis; the balloon or stent catheter passed over it and the lesion dilated and/or stented.

Femoral approach and complications

The usual approach is the femoral approach which uses the body's highway to access the coronary ostium. Complications are usually quoted between two per cent and eight per cent after femoral PCI. Bleeding associated with the femoral access sites is the most common complication. Very rarely, the patient requires transfusion for unrecognised retroperitoneal bleeding. Arterovenous fistulas and pseudoaneurysms may need surgical intervention.

Other complications common to both approaches are uncommon. Known cases of contrast allergy receive premedication with methylprednisolone, antihistamines and H2 blockers. Potential serious complications include periprocedural myocardial infarction (incidence <one per cent) and stroke. Dissections or coronary perforations may require emergency cardiac surgery. Periprocedural mortality is associated with underlying severe disease of the left main stem and cardiogenic shock.



Complications

First described in 1989, now widely used in Europe and Japan, the use of forearm angiography has a lower complication rate and a higher degree of patient comfort. The hand receives a dual arterial supply from the radial and ulnar arteries, which come together to form deep and superficial palmar arches. The radial artery, unlike the femoral or brachial artery, is therefore

not an end artery, and, in the presence of a satisfactory ulnar collateral supply, its occlusion does not compromise the vascular supply to the hand. Furthermore, the superficial course of the distal radial artery provides for easy compression of the artery, so that patients can mobilise as soon as the arterial sheath is removed on completion of the procedure.

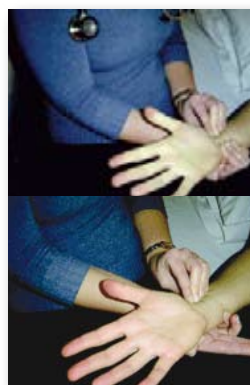
The incidence of bleeding complications with radial access is negligible even in patients treated with aggressive antithrombotic regimens. Post PCI transfusion-status is an important independent predictor of one year mortality. Wrist angioplasty is associated with 50 per cent less blood transfusions and lower mortality. This is shown in the M.O.R.T.A.L. Study (Mortality benefit of Reduced Transfusion After PCI via the Arm or Leg) of the 32,000 patients.

In morbidly obese patients, transradial approach allows for easier access and easier hemostasis. With more sophisticated anticoagulation regimens like the use of GPIIb/IIIa agents and routine use of double antiplatelet agents, the impact on the risk of bleeding can be lessened with the radial approach.

Possible nerve trauma is less as the only nerve in close proximity is the superficial branch of the radial nerve which is the sensory nerve supplying the outer aspect of the thumb.

Technical considerations

The transradial approach is not for everyone. First, the Allen test is performed to confirm a dual blood supply to the hand via a radial and an ulnar artery. In the Allen test, the palm is rendered ischaemic by clenching and opening the hand during compression of the radial and ulnar arteries, the test is positive (normal) if the palm colouration returns to normal within 10 seconds of release of compression of the ulnar artery while radial artery compression is maintained. Patients with abnormal Allen's tests should undergo the femoral approach.



The transradial approach is technically more difficult. The radial artery is smaller and more prone to spasm. The subclavian artery is more tortuous making passage of the catheter, balloons and stents more difficult. The single most important reason for the low adoption rate is the lack of trained cardiologists in this technique. Otherwise, dedicated introducer sheaths in smaller sizes and specially designed catheters are widely available. Complex angioplasty including rotablation can be performed via the transradial approach.

(continue on page 8)